

# Anesthesia Management in a Rare Case: Wolf-Hirschhorn Syndrome

## Nadir Bir Olguda Anestezi Yönetimi: Wolf-Hirschhorn Sendromu

Özgün Ömer Asiller, Ezgi Yıldırım, Barış Sakul, Menekşe Özçelik

Ankara University Faculty of Medicine, Department of Anesthesiology and Reanimation, Ankara, Türkiye

### Abstract

Wolf-Hirschhorn syndrome is a rare disease and may cause difficulties in airway management. In addition, intraoperative complications may occur. We will share with you our anesthesia management experience in a patient who is scheduled to undergo repair due to a cleft lip.

**Keywords:** Wolf-Hirschhorn syndrome, pediatric anesthesia, rare diseases

### Öz

Wolf-Hirschhorn sendromu nadir görülen bir hastalıktır ve hava yolu yönetiminde zorluklara neden olabilir. Ayrıca, intraoperatif komplikasyonlar meydana gelebilir. Dudak yarığı nedeniyle onarım planlanan bir hastada anestezi yönetimi deneyimimizi sizinle paylaşacağız.

**Anahtar Kelimeler:** Wolf-Hirschhorn sendromu, pediatrik anestezi, nadir hastalıklar

### Introduction

Wolf-Hirschhorn syndrome (WHS) (-) is characterized by 4p deletion and is characterized by pre- and postnatal growth retardation, cognitive dysfunction, epilepsy, and typical craniofacial components such as nasal hypertelorism, microcephaly, high forehead with prominent glabella, ocular hypertelorism, epicanthus, high arched eyebrows, short philtrum, downturned "fish like", micrognathia and underdeveloped ears. Prominent forehead, hypertelorism, and broad nasal bridge continuing toward the forehead caused the term "Greek warrior helmet appearance". This syndrome was first described by Hirschhorn and Cooper (1) in 1961. A second case was described by Wolf et al. (2). There is a 2:1 female:male ratio, with a frequency of 1:50,000-1:20,000 births. Various factors play a role in growth delay, including oral facial clefts, difficulty in sucking, poorly coordinated swallowing resulting in aspiration, and

gastroesophageal (3,4). WHS is associated with a high mortality rate of approximately 30% in the first 2 years of life, and the most common causes of death are lower respiratory tract infections and congenital heart disease/heart failure (5). In this article, we will present a case of WHS who was operated for cleft palate.

### Case Presentation

A cleft palate operation was planned for our patient who weighed 13 kg and 93 cm when she was 4 years and 39 weeks old. We obtained consent form from her family. Our patient with intrauterine growth retardation was followed up in the neonatal intensive care unit for 2.5 months without being intubated after she was born via cesarean section at 34 weeks and weighed 1300 gr. There was no consanguinity in her family history. Our patient was diagnosed with WHS when she was 5 months old. When she was diagnosed, ventricular septal defects (VSD), atrial septal

Address for Correspondence/Yazışma Adresi: Özgün Ömer Asiller

Ankara University Faculty of Medicine, Department of Anesthesiology and Reanimation, Ankara, Türkiye

E-mail: omerasiller@gmail.com ORCID ID: orcid.org/0000-0002-9573-4730

Received/Geliş Tarihi: 27.09.2024 Accepted/Kabul Tarihi: 01.06.2025 Epub: 16.06.2025 Publication Date/Yayınlanma Tarihi: 27.06.2025

Cite this article as/Atf: Asiller ÖÖ, Yıldırım E, Sakul B, Özçelik M. Anesthesia management in a rare case: Wolf-Hirschhorn syndrome. J Ankara Univ Fac Med. 2025;78(2):164-166



defects (ASD), hypotonia, and epilepsy were present. The patient complained of frequent vomiting and had a history of intensive care hospitalization once due to aspiration pneumonia. The drugs she used were levetiracetam and growth hormone. There was only cleft lip surgery as in the previous operation. Hypertolerism and coarseness of breath sounds were the physical examination findings (Figures 1 and 2). In the last cardiology examination, ASD and VSD were closed. In the preoperative blood examination, potassium was 5.2 mmol/L, calcium: 11.3 mg/dL, phosphorus: 4.6 mg/dL, and the remaining electrolytes were normal. The vitamin D level was 31.17 ng/mL. In the thyroid function test, T4 and TSH were normal and only T3 was 7.8 pmol/L (upper limit 6.8). There were no abnormalities in hemoglobin, platelet, and bleeding parameters.

Solid food intake was stopped 8 h before the surgery, and liquid food intake was stopped with levetiracetam 4 h before the surgery. When she came to the operating room, the American Society of Anesthesiologists recommended monitoring was performed. Due to severe preoperative anxiety and inability

to remain still, it was not possible to insert an intravenous line before induction. Therefore, inhalational induction with sevoflurane was preferred in order to avoid further distress and facilitate IV access in a controlled manner. The patient was induced with 1–8% sevoflurane. A nasogastric tube was inserted immediately after induction. One 24G and one 22G IV catheter were opened. The patient was started with 0.9% isotonic and 1/3 dextrose as fluid, and hourly blood glucose monitoring was planned. The patient was administered 5 mg ketamine, 5 mg fentanyl, and 5 mg lidocaine, followed by 60 mg propofol. Nasal intubation was performed using a 3.5-cuffed tube with a videolaryngoscope. The temperature probe was placed on the left axilla. Anesthesia was maintained with sevoflurane with MAC of 0.7. The patient whose hourly maintenance fluid was 130 mL became hypotensive at the minute 160 of the operation. Fluid boluses of 10 mL per kilo were administered three times. After fluid responsiveness, adrenaline infusion of 0.02 mcg/kg/min was initiated. Sevoflurane was turned off at minute 196. The patient was extubated at the minute 216. The patient was admitted to the postoperative care unit for 40 min. She was discharged on the day 3 after the operation.

## Discussion

Airway evaluation is important during preoperative evaluation. Due to the developmental delay of the patient, a smaller endotracheal tube may be required than that used in the normal age group in addition to difficult airway preparation (5,6). At this stage, the tracheal diameter at the c6 level is important (7). Heart defects reported in 50% of children with WHS are generally uncomplicated and are characterized by atrial and VSD, pulmonary stenosis, and patent ductus arteriosus associated with aortic regurgitation (3). Preoperative electrocardiogram and echocardiography should be performed in variants containing congenital heart disease (7).

On the day of surgery, patients should be administered antiepileptics (8). At this stage, the plasma concentration of many drugs will decrease because of drugs that increase liver enzyme activity, such as carbamazepine, phenobarbital, and phenytoin; if valproate is used, the metabolism of most drugs will be slowed down because of the inhibition of microsomal hepatic enzymes (9). If the patient is taking valproate for seizures, bleeding parameters and platelet function should be evaluated (10).

Antibody deficiencies have been reported in 69% of children with WHS (3). If the patient also has Ig-A deficiency, the patient may have an allergic or anaphylactic reaction to transfusions (11).

Although there is no obstacle in induction with inhalation, there is a risk of aspiration because gastroesophageal reflux may occur in this patient group (12).

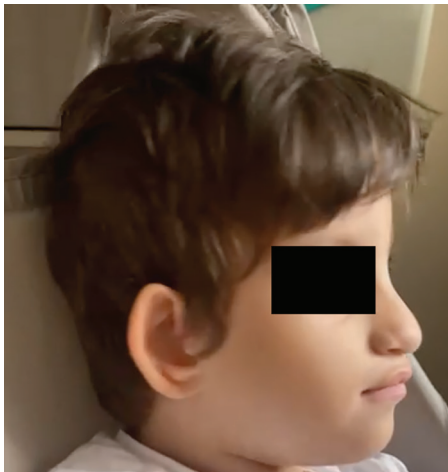

Figure 1: Physical examination from side

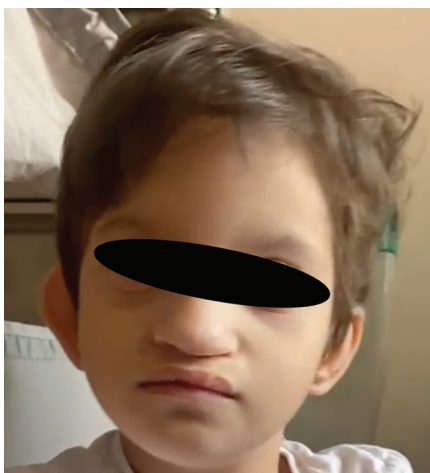


Figure 2: Physical examination from front

If a patient with WHS develops fever during and after anesthesia, anesthetists should also consider malignant hyperthermia and other causes. Various unusual conditions during anesthesia may resemble malignant hyperthermia. These include iatrogenic overheating, infection, transfusion reaction, central nervous system dysfunction, allergic reactions, pheochromocytoma, thyrotoxicosis, drug-induced hyperthermia (tricyclic antidepressants, monoamine oxidase inhibitors, anticholinergics, amphetamines, etc.), machine valve malfunction, and rebreathing. The presence of a high temperature in the patient immediately after surgery may be associated with conditions such as sepsis or drug reaction, and this requires appropriate investigation. During this process, the risk of febrile convulsions due to hyperthermia should be avoided. Therefore, the patient should be provided with normothermia (6).

Malignant hyperthermia related to this syndrome has been observed in two cases till date (13,14), and one of them developed postoperatively (14). Generalized hypotonia, a feature of WHS, is usually associated with muscle hypotrophy of the lower legs (3). Doses of neuromuscular blocking agents should be titrated when the patient presents with generalized hypotonia (8). In addition to these, no relationship was found between malignant hyperthermia and WHS (ryanodine receptors are not genetically affected) (12-16).

### Ethics

**Informed Consent:** Informed consent was obtained both orally and in writing from the patient's legal representative.

### Footnotes

### Authorship Contributions

Surgical and Medical Practices: Ö.Ö.A., E.Y., B.S., Concept: M.Ö., Data Collection and/or Processing: B.S., Analysis and/or Interpretation: Ö.Ö.A., E.Y., Literature Search: E.Y., Writing: Ö.Ö.A., M.Ö.

**Conflict of Interest:** The authors declared no conflicts of interest with respect to the authorship and/or publication of this article.

**Financial Disclosure:** The authors received no financial support for the research and/or authorship of this article.

### References

1. Hirschhorn K, Cooper HL. Chromosomal aberrations in human disease. A review of the status of cytogenetics in medicine. *Am J Med.* 1961;31:442-470.
2. Wolf U, Reinwein H, Porsch R, Schröter R, Baitsch H. [Deficiency on the short arms of a chromosome No. 4]. *Humangenetik.* 1965;1:397-413.
3. Battaglia A, Carey JC, South ST. Wolf-Hirschhorn syndrome: A review and update. *Am J Med Genet C Semin Med Genet.* 2015;169:216-223.
4. Battaglia A, Filippi T, Carey JC. Update on the clinical features and natural history of Wolf-Hirschhorn (4p-) syndrome: Experience with 87 patients and recommendations for routine health supervision. *Am J Med Genet C Semin Med Genet.* 2008;148C:246-251.
5. Gamble JF, Kurian DJ, Udani AG, Greene NH. Airway management in a patient with Wolf-Hirschhorn syndrome. *Case Rep Pediatr.* 2016;2016:7070125.
6. Choi JH, Kim JH, Park YC, Kim WY, Lee Y-S. Anesthetic experience using total intra-venous anesthesia for a patient with Wolf-Hirschhorn syndrome-A case report. *Korean J Anesthesiol.* 2011;60:119-123.
7. Tsukamoto M, Yamanaka H, Yokoyama T. Anesthetic considerations for a pediatric patient with Wolf-Hirschhorn syndrome: a case report. *J Dent Anesth Pain Med.* 2017;17:231.
8. Kim HJ, You JA, Park S, Kim EJ, Park SJ, Kim HY. Anesthetic considerations for an adult with Wolf-Hirschhorn syndrome - A case report. *Anesth Pain Med (Seoul).* 2020;15:120-123.
9. Bloor M, Nandi R, Thomas M. Antiepileptic drugs and anesthesia. *Paediatr Anaesth.* 2017;27:248-250.
10. Abdallah C. Considerations in perioperative assessment of valproic acid coagulopathy. *J Anaesthesiol Clin Pharmacol.* 2014;30:7.
11. Sandler SG, Mallory D, Malamut D, Eckrich R. IgA anaphylactic transfusion reactions. *Transfus Med Rev.* 1995;9:1-8.
12. Bosenberg A. Anaesthesia and Wolf-Hirschhorn syndrome. *SAJAA.* 2014;13:31-34.
13. Ginsburg R, Purcell-Jones G. Malignant hyperthermia in the Wolf-Hirschhorn syndrome. *Anaesthesia.* 1988;43:386-388.
14. Chen JC, Jen RK, Hsu YW, et al. [4P- syndrome (Wolf-Hirschhorn syndrome) complicated with delay onset of malignant hyperthermia: a case report]. *Acta Anaesthesiol Sin.* 1994;32:275-278.
15. Hulin J, Veyckemans F. [Anaesthetic management of the Wolf-Hirschhorn syndrome: a report of two cases]. *Ann Fr Anesth Reanim.* 2012;31:89-90.
16. Humston C, Bernard R, Khan S, Tobias JD. Perioperative care of an infant with wolf-hirschhorn syndrome: is there a risk of malignant hyperthermia. *J Med Cases.* 2016;7:126-129.