

# Comparison of FOLFOX/CAPOX and Sorafenib in Locally Advanced or Metastatic Hepatocellular Carcinoma

## Lokal İleri veya Metastatik Hepatoselüler Karsinomda FOLFOX/CAPOX ve Sorafenib Karşılaştırması

Merih Yalçiner, Efe Cem Erdat, Beliz Bahar Karaođlan, Hatice Bölek, Elif Berna Köksoy

Ankara University Faculty of Medicine, Department of Medical Oncology, Ankara, Türkiye

### Abstract

**Objectives:** Liver cancer ranks third in terms of mortality worldwide. Sorafenib is a tyrosine kinase inhibitor that was approved for patients with advanced hepatocellular cancer (HCC). There are not many large-scale studies comparing sorafenib with chemotherapy. We planned to compare the effectiveness of sorafenib and chemotherapy in advanced-stage HCC patients.

**Materials and Methods:** Patients over the age of 18, who were followed up with a diagnosis of advanced stage HCC in the Medical Oncology Department at Ankara University Faculty of Medicine between 2012 and 2022, who received sorafenib or FOLFOX/CAPOX treatment as first-line treatment, were included in the study. Patient and disease characteristics were recorded from the hospital database (Avicenna) and compared statistically.

**Results:** Forty-four patients were included. The Eastern Cooperative Oncology Group performance status of all patients was 0-1. Nine (22.5%) patients had liver cirrhosis. The distribution of Child-Pugh scores was similar between groups ( $p=0.45$ ). It was seen that 22 (50%) patients had stage A-B disease and 22 (50%) patients had stage C disease. It was recorded that 37 (84.1%) patients received sorafenib and 7 (15.9%) patients received FOLFOX/CAPOX treatment. Progression-free survival was measured as 2 months for the FOLFOX/CAPOX arm and 1 month for the sorafenib arm ( $p=0.96$ , log-rank). Overall survival was measured as 8.8 months in the FOLFOX/CAPOX arm and 6.3 months in the sorafenib arm ( $p=0.29$ , log-rank).

**Conclusion:** No difference in survival was demonstrated between sorafenib and FOLFOX/CAPOX treatment. Multicenter and larger population studies are needed to elucidate the place of fluoropyrimidine and oxaliplatin combination in HCC treatment.

**Keywords:** Hepatocellular carcinoma, liver cancer, chemotherapy, sorafenib

### Öz

**Amaç:** Karaciğer kanseri, akciğer ve kolorektal kanserden sonra dünya çapında mortalite açısından üçüncü sırada yer almaktadır. Sorafenib, 2007 yılında inoperabl hepatoselüler kanser (HCC) hastalarında onay almış bir tirozin kinaz inhibitörüdür. Sorafenibin kemoterapi ile kıyaslandığı geniş çaplı fazla sayıda çalışma olmadığı görülmektedir. Bu çalışmada ileri evre HCC hastalarında sorafenib ile kemoterapi etkinliğinin karşılaştırılması planlandı.

**Gereç ve Yöntem:** Ankara Üniversitesi Tıp Fakültesi, Tıbbi Onkoloji bölümünde 2012-2022 arasında ileri evre HCC tanısı ile takip edilen, birinci basamak tedavide sorafenib veya FOLFOX/CAPOX tedavisi alan, 18 yaş üzerindeki hastalar çalışmaya dahil edildi. Hasta ve hastalık özellikleri hastane veritabanından (Avicenna) kaydedildi ve istatistiki olarak karşılaştırıldı.

**Bulgular:** Çalışmaya 44 hasta dahil edildi. Tüm hastaların Dođu Kooperatif Onkoloji Grubu performans durumu 0-1 idi. Dokuz (%22,5) hastada karaciğer sirozu mevcuttu. Tümör evreleri değerlendirildiğinde 22 (%50) hastada evre A-B, 22 (%50) hastada evre C hastalık olduğu görüldü. Sistemik tedavilerde 37 (%84,1) hastanın sorafenib, 7 (%15,9) hastanın FOLFOX/CAPOX tedavisi aldığı kaydedildi. Child-Pugh skorlarının dağılımı gruplar arasında benzerdi ( $p=0,45$ ). Progresyonsuz sağkalım FOLFOX/CAPOX kolu için 2 ay, sorafenib kolu için 1 ay olarak ölçüldü ( $p=0,96$ , log-rank). Genel sağkalım FOLFOX/CAPOX kolunda 8,8 ay, sorafenib kolunda ise 6,3 ay olarak ölçüldü ( $p=0,29$ , log-rank).

**Sonuç:** Sorafenib ile FOLFOX/CAPOX tedavisi arasında sağkalım açısından fark gösterilemedi. Fluoropirimidin ve okzaliptatin kombinasyonunun HCC tedavisindeki yerinin aydınlatılması için çok merkezli ve daha geniş popülasyonlu çalışmalara gereksinim vardır.

**Anahtar Kelimeler:** Hepatoselüler karsinom, karaciğer kanseri, kemoterapi, sorafenib

Address for Correspondence/Yazışma Adresi: Merih Yalçiner

Ankara University Faculty of Medicine, Department of Medical Oncology, Ankara, Türkiye

E-mail: merihyalciner@gmail.com ORCID ID: orcid.org/0000-0003-3337-2188

Received/Geliş Tarihi: 01.05.2024 Accepted/Kabul Tarihi: 19.10.2024



Copyright© 2024 The Author. Published by Galenos Publishing House on behalf of Ankara University Faculty of Medicine. This is an open access article under the Creative Commons AttributionNonCommercial 4.0 International (CC BY-NC 4.0) License.

## Introduction

Liver cancer ranks third in terms of mortality worldwide, after lung and colorectal cancer (1). Hepatocellular carcinoma (HCC) is the most common type of primary liver cancer, with a rate of around 80% (2). New treatment options for this disease, which has a very high mortality rate, especially in the advanced stages, are an important research topic in the oncology literature.

The Barcelona Clinic Liver Cancer (BCLC) system, which is widely accepted for staging and treatment selection, integrates the Child-Pugh score, which is used as the gold standard in determining liver functional reserve, apart from the extent of the disease (3,4). This system is widely used in HCC treatment decision. Among the new systemic treatments for advanced stage patients who are not suitable for local treatments, the combination of atezolizumab and bevacizumab, which has been shown to be superior to sorafenib, and the combination of durvalumab and tremelimumab, stand out (5,6). However, it is not possible to use these agents in many patients due to reasons such as availability of the drugs and reimbursement conditions.

Sorafenib is a tyrosine kinase inhibitor (TKI) approved in 2007 for inoperable HCC patients and is now widely used in advanced-stage disease. Sorafenib was compared with placebo in its study in advanced disease, with median survivals reported as 10.7 and 7.9 months, respectively (7). Although it is known that the effectiveness of chemotherapy is limited, especially in patients with chronic liver disease-related complications and high volume disease (8), after the approval of sorafenib, it appears that there are not many large-scale studies comparing sorafenib with chemotherapy. A recently published study has shown that hepatic artery infusion of fluorouracil (5-FU) and oxaliplatin (OXA) may be superior to sorafenib in disease limited to the liver (9).

In this study, we planned to compare the effectiveness of sorafenib and chemotherapy in advanced-stage HCC patients.

## Materials and Methods

The study was conducted in accordance with the Declaration of Helsinki and Regulations in drug research Ministry of Health, Government of Türkiye, January 29,1993. Ankara University Faculty of Medicine Ethics committee approved the study protocol (decision no.: İ03-280-24, date:24.04.2024). All patients signed informed consent to participate in retrospective studies before initial presentation.

Patients over the age of 18, who were diagnosed with advanced stage HCC and were treated with sorafenib or FOLFOX/CAPOX in first-line treatment, at Ankara University Faculty of Medicine, Medical Oncology Department between 2012 and 2022, were included in the study. Previous trans-

arterial chemo-embolization treatment was not considered an exclusion criteria. Patients who did not receive sorafenib or FOLFOX/CAPOX chemotherapy in first-line treatment, who had a local treatment option and whose data were not available were excluded. Information such as age, comorbidities, HCC etiology, BCLC stage, previous local treatments, Child-Pugh score, encephalopathy and ascites status were recorded from the hospital database (Avicenna).

## Statistical Analysis

Statistical analysis was performed with R version 4.1 (R foundation) program. The distribution of variables was evaluated visually (histogram and probability plots) and analytically (Kolmogorov-Smirnov/Shapiro-Wilk tests, according to number of patients). Descriptive statistics were given as mean and standard deviation for normally distributed variables. Chi-Square test was used to compare categorical variables. Kaplan-Meier analysis and log-rank test were used for survival tests, including analysis for progression free and overall survival for FOLFOX/CAPOX and sorafenib treatments. For statistical significance, type-1 error level was accepted as 5%.

## Results

Forty-four patients were included in the study. Forty patients (91%) were male and 4 patients (9%) were female. The Eastern Cooperative Oncology Group performance status of all patients was 0-1. When comorbidities were evaluated, 14 (31.8%) patients had hypertension, 15 (34.1%) patients had diabetes mellitus, and 7 (15.9%) patients had atherosclerotic cardiovascular disease. Nine (22.5%) patients had liver cirrhosis. When the Barcelona stages of the tumor were evaluated, it was seen that 22 (50%) patients had stage A-B disease and 22 (50%) patients had stage C disease. When the etiology was examined, it was seen that 21 (47.7%) patients had hepatitis B and 4 (9.1%) patients had hepatitis C. Thirty-two (72.7%) patients received local treatment before systemic treatment. In systemic treatments, 37 (84.1%) patients received sorafenib and 7 (15.9%) patients received FOLFOX/CAPOX treatment. The clinical characteristics of the patients are summarized in Table 1.

It was observed that 22 (59.4%) of 37 patients receiving sorafenib were Child-Pugh category A, and 15 (40.5%) were B. It was noted that in the FOLFOX/CAPOX group, 3 (42.9%) patients were category A and 4 (57.1) patients were category B. There were no Child-Pugh C patients. The distribution of Child-Pugh scores was similar between groups ( $p=0.45$ ). While ascites was not observed in 27 (72.9%) patients in the sorafenib group, ascites was slight in 9 (24.3%) patients and moderate in 1 (2.7%) patient. In the FOLFOX/CAPOX group, 2 (28.6%) patients had slight ascites. There was no difference between the groups in terms of ascites. Hepatic encephalopathy was not observed in any patient (Table 2).

Table 1. Patient characteristics				
	Male (n=40)	Female (n=4)	Total (n=44)	p-value
Age, mean (+/- SD)	65.5 (9.22)	59.3 (18.2)	64.9 (10.2)	0.25
ECOG performance status 0-1, n (%)	40 (100%)	4 (100%)	44 (100%)	
<b>Comorbidities, n (%)</b>				
Hypertension	12 (30%)	2 (50%)	14 (31.8%)	0.41
Diabetes mellitus	13 (32.5%)	2 (50%)	15 (34.1%)	0.48
Atherosclerotic cardiovascular disease	7 (17.5%)	-	7 (15.9%)	0.36
Cirrhosis	9 (22.5%)	-	9 (20.5%)	0.29
<b>Stage (Barcelona)</b>				
A-B	21 (42.5%)	1 (25%)	22 (50%)	0.50
C	19 (47.5%)	3 (75%)	22 (50%)	
<b>HCC etiology</b>				
Hepatitis B	19 (47.5%)	2 (50%)	21 (47.7%)	0.74
Hepatitis C	3 (7.5%)	1 (25%)	4 (9.1%)	
Other/unknown	18 (45%)	1 (25%)	19 (43.2%)	
<b>Local treatment</b>	30 (75%)	2 (50%)	32 (72.7%)	0.28
<b>Systemic treatment</b>				
Sorafenib	34 (85%)	3 (75%)	37 (84.1%)	0.60
FOLFOX/CAPOX	6 (15%)	1 (25%)	7 (15.9%)	

SD: Standard deviation, ECOG: Eastern Cooperative Oncology Group

Table 2. Distribution of patients according to Child-Pugh scores and ascites status				
	Sorafenib (n=37)	FOLFOX/CAPOX (n=7)	Total (n=44)	p-value
<b>Child-Pugh</b>				
A	22 (59.4%)	3 (42.9%)	25 (56.8%)	0.45
B	15 (40.5%)	4 (57.1%)	19 (43.2%)	
<b>Ascites</b>				
Absent	27 (72.9%)	5 (71.4%)	32 (72.7%)	0.89
Slight	9 (24.3%)	2 (28.6%)	11 (25%)	
Moderate	1 (2.7%)	-	1 (2.2%)	
<b>No encephalopathy</b>	37 (100%)	7 (100%)	44 (100%)	

Progression-free survival was measured as 2 months for the FOLFOX/CAPOX arm and 1 month for the sorafenib arm ( $p=0.96$ , log-rank, Figure 1).

Overall survival was measured as 8.8 months in the FOLFOX/CAPOX arm and 6.3 months in the sorafenib arm ( $p=0.29$ , log-rank, Figure 2).

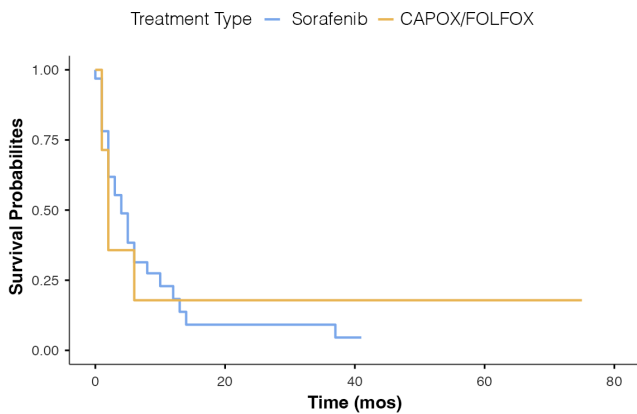
## Discussion

The results of our study show that there is no difference in overall and progression-free survival between FOLFOX/CAPOX and sorafenib. Although our study has limitations such as a small and heterogeneous patient population, possible data loss due to retrospective design, and being a single-center study, it contributes to the literature since there are very few studies

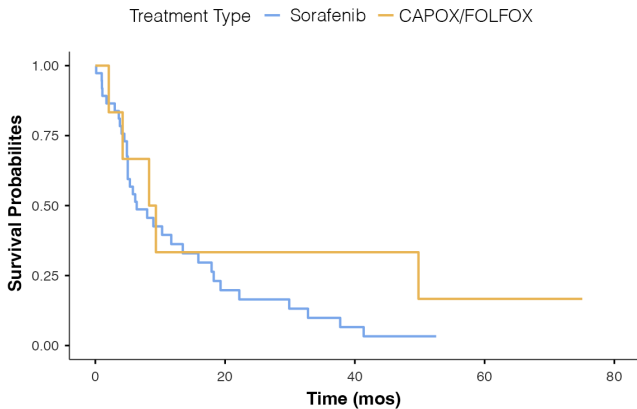
comparing chemotherapy with sorafenib in the treatment of HCC.

It is known that chemotherapy has limited effectiveness in the treatment of HCC and optimal chemotherapy regimen is unknown. Although response rates are low, there is evidence in the literature that these rates are affected by factors such as tumor burden, performance status, tumor thrombus and bilirubin level (8).

Sorafenib is a TKI approved in 2007 for inoperable HCC patients and is now widely used in advanced stage disease (7). It is known that for this disease, where mortality is quite high and treatment options are limited, the number of agents that demonstrate a survival advantage is quite low. Although the median survival with sorafenib was reported as 10.7 months in



**Figure 1:** Progression-free survival in patients receiving FOLFOX/CAPOX and sorafenib



**Figure 2:** Overall survival in patients receiving FOLFOX/CAPOX and sorafenib

the SHARP trial, a point that should be noted in this study is that the drug was compared with placebo. Although there are trials for immunotherapy and other tyrosine kinase inhibitors in the literature (10,11), there do not seem to be many studies comparing chemotherapy with sorafenib. In a phase 3 trial, which included 356 patients, comparing sorafenib alone and the sorafenib-doxorubicin combination, no significant difference on survival could be demonstrated (12). In another phase 2 trial which included 94 patients, sorafenib alone and the gemcitabine-OXA-sorafenib combination were compared. Although a better objective response rate was achieved in the chemotherapy arm, no significant progression-free survival advantage was demonstrated (13). It appears that sorafenib has not been compared head-to-head with chemotherapy in large-scale studies. In addition, availability of immunotherapy and other combination treatments, which have been shown to be superior in first-line treatment in advanced disease, is limited, and there appears to be an unmet need in advanced disease.

In our study, no superiority of sorafenib over FOLFOX/CAPOX chemotherapy was observed in first-line treatment of HCC patients who were not suitable for local treatment options. In addition, overall survival was observed to be longer in patients who responded to FOLFOX/CAPOX treatment, despite not reaching statistical significance, probably due to low patient count. In a recent phase 3 trial including 262 patients, hepatic arterial infusion of 5-FU/OXA treatment was compared with sorafenib, and overall survival was reported as 13.9 and 8.2 months, respectively (9). An important point in this study is that local treatments could be applied to 16 patients after treatment, and the median survival in this group was reported as 20.8 months, while survival in high-risk patients was reported as 5.7 months versus 10.8 months. In another phase 3 trial comparing sorafenib alone with the combination of hepatic arterial infusion chemotherapy in patients with portal vein tumor thrombosis, a sign of high risk and poor prognosis, survivals were reported as 16.3 and 6.5 months, respectively (14). However, it was also reported in this study that the toxicity of combination therapy was higher. These studies suggest that 5-FU and OXA chemotherapy regimens may be effective in the treatment of HCC and are consistent with the findings of our study. These findings suggest that 5-FU and OXA chemotherapy may provide a survival advantage in some patient subgroups. Since our study included a small number of patients, it was not possible to assess the subgroups in which chemotherapy could be most beneficial. Identification of these patient subgroups and factors that may indicate chemotherapy sensitivity is crucial, especially for a patient population that has limited access to new combination therapies that have been shown to be superior to sorafenib, and may guide individualization of treatment and provide a survival advantage in this patient group.

In conclusion, no difference in survival was demonstrated between sorafenib and FOLFOX/CAPOX treatment in our study. Multicenter and larger population studies are needed to elucidate the place of fluoropyrimidine and OXA combination in HCC treatment.

## Ethics

**Ethics Committee Approval:** The study was conducted in accordance with the Declaration of Helsinki and Regulations in drug research Ministry of Health, Government of Türkiye, January 29,1993. Ankara University Faculty of Medicine Ethics committee approved the study protocol (decision no.: İ03-280-24, date:24.04.2024).

**Informed Consent:** All patients signed informed consent to participate in retrospective studies before initial presentation.

**Acknowledgements:** We would like to express our sincere gratitude to all professors and staff we work together in our clinic for their continuous support.

## Footnotes

### Authorship Contributions

Concept: M.Y., E.C.E., E.B.K., Design: M.Y., E.B.K., Data Collection and/or Processing: M.Y., B.B.K., H.B., Analysis and/or Interpretation: E.C.E., Literature Search: E.C.E., B.B.K., H.B., Writing: M.Y., E.B.K.

**Conflict of Interest:** There is no potential conflict of interest to declare.

**Financial Disclosure:** This study received no financial support.

## References

1. Rumgay H, Arnold M, Ferlay J, et al. Global burden of primary liver cancer in 2020 and predictions to 2040. *J Hepatol.* 2022;77:1598-1606.
2. Rumgay H, Ferlay J, de Martel C, et al. Global, regional and national burden of primary liver cancer by subtype. *Eur J Cancer.* 2022;161:108-118.
3. Reig M, Forner A, Rimola J, et al. BCLC strategy for prognosis prediction and treatment recommendation: the 2022 update. *J Hepatol.* 2022;76:681-693.
4. Child CG, Turcotte JG. Surgery and portal hypertension. *Major Probl Clin Surg.* 1964;1:1-85.
5. Abou-Alfa GK, Chan SL, Kudo M, et al. Phase 3 randomized, open-label, multicenter study of tremelimumab (T) and durvalumab (D) as first-line therapy in patients (pts) with unresectable hepatocellular carcinoma (uHCC): HIMALAYA. *Journal of Clinical Oncology.* 2022;40:379-379.
6. Finn RS, Qin S, Ikeda M, et al. Atezolizumab plus bevacizumab in unresectable hepatocellular carcinoma. *New England Journal of Medicine.* 2020;382:1894-1905.
7. Llovet JM, Ricci S, Mazzaferro V, et al. Sorafenib in advanced hepatocellular carcinoma. *New England Journal of Medicine.* 2008;359:378-390.
8. Nagahama H, Okada S, Okusaka T, et al. Predictive factors for tumor response to systemic chemotherapy in patients with hepatocellular carcinoma. *Jpn J Clin Oncol.* 1997;27:321-324.
9. Lyu N, Wang X, Li J-B, et al. Arterial chemotherapy of oxaliplatin plus fluorouracil versus sorafenib in advanced hepatocellular carcinoma: a biomolecular exploratory, randomized, phase III trial (FOHAIC-1). *Journal of Clinical Oncology.* 2022;40:468-480.
10. Yau T, Park J-W, Finn RS, et al. Nivolumab versus sorafenib in advanced hepatocellular carcinoma (CheckMate 459): a randomised, multicentre, open-label, phase 3 trial. *Lancet Oncol.* 2022;23:77-90.
11. Kudo M, Finn RS, Qin S, et al. Lenvatinib versus sorafenib in first-line treatment of patients with unresectable hepatocellular carcinoma: a randomised phase 3 non-inferiority trial. *The Lancet.* 2018;391:1163-1173.
12. Abou-Alfa GK, Shi Q, Knox JJ, et al. Assessment of treatment with sorafenib plus doxorubicin vs sorafenib alone in patients with advanced hepatocellular carcinoma. *JAMA Oncol.* 2019;5:1582-1588.
13. Assenat E, Pageaux G-P, Thézenas S, et al. Sorafenib alone vs. sorafenib plus GEMOX as 1st-line treatment for advanced HCC: the phase II randomised PRODIGE 10 trial. *Br J Cancer.* 2019;120:896-902.
14. Zheng K, Zhu X, Fu S, et al. Sorafenib plus hepatic arterial infusion chemotherapy versus sorafenib for hepatocellular carcinoma with major portal vein tumor thrombosis: a randomized trial. *Radiology.* 2022;303:455-464.