

# An Unusual Localization Of Spontaneous Gastric Perforation: A Case Report

Nadir Yerleşimli Spontan Gastrik Perforasyonu: Bir Olgu Sunumu

Mert Demirel<sup>1</sup>, Kürşat Karadayı<sup>2</sup>, Savaş Serel<sup>3</sup>, Murat Emiroğlu<sup>3</sup>

<sup>1</sup> Plastic, Reconstructive Surgery Clinic, Kahramanmaraş Government Hospital, Kahramanmaraş, Turkey

<sup>2</sup> Department of General Surgery, Sivas Cumhuriyet University, Faculty of Medicine, Sivas Turkey

<sup>3</sup> Department of Plastic, Reconstructive and Aesthetic Surgery, Ankara University, Faculty of Medicine, Ankara, Turkey.

75 yaşında erkek hasta, sol frontal bölgesinde yer alan bir kitle nedeniyle kliniğimize başvurdu. Yapılan insizyonel biyopsi sonucu saçlı deriye ait yassı hücreli kanser olarak değerlendirildi. Tümör geniş olarak eksize edilip, sol radial ön kol flebi ile rekonstrükte edildi. Operasyondan bir gün sonra lokalize edilemeyen epigastrik ağrı ve kontrol edilemeyen hıçkırma şikayetleri başladı. Düz postero-anterior abdominal grafi ve bilgisayarlı tomografi görüntülerinde diaframın altında oldukça fazla miktarda serbest hava tespit edildi. Gastrointestinal perforasyon ön tanısı ile laparotomi yapıldı. Gastrik fundusun posterior duvarında bir perforasyon saptandı ve onarıldı. Erken postoperatif dönemde problemi olmayan hasta 10. günde myokardial enfarktüse bağlı olarak ex oldu. Bu hastada saptanan ve olgu sunumumuzda incelenen posterior gastrik duvardaki spontan perforasyon nadir görülen bir durumdur.

**Anahtar Sözcükler:** *Spontan gastrik perforasyon, serbest flep komplikasyonu, stress ülseri*

A 75 year-old male patient was admitted to Plastic Surgery Department complained a painless mass on his left frontal skin area. Histopathological examination was diagnosed the squamous cell carcinoma of the scalp. The tumor was excised widely and reconstructed with a left Chinese free flap. An unlocalised epigastric pain and uncontrolled hiccups was started on the first day after the operation. A plain abdominal roentgenogram and computed tomography demonstrated a large amount free air under the diaphragm. A laparotomy was performed under the diagnosis of gastrointestinal perforation, a perforation of the posterior wall of the gastric fundus was found. The patient died due to myocardial infarct on postoperative ten days. Spontaneous gastric perforation is very rare condition.

**Key Words:** *Spontaneous gastric perforation, free flap complication, stress ulcer*

Gastric perforations are very common emergencies of medicine<sup>1</sup>. Spontaneous gastric perforations are met in adults, neonates and preschool age children (2-4). Almost all gastric perforations have comorbiditant factors. These factors are; Peptic ulcer(1), Zollinger Ellison Syndrome(5), Primary(6) or Secondary(7-9) malignancies of stomach, external(10), or internal traumatic conditions, medications(11). Classical peptic ulcer perforation is localized on pylor and bulbus of duodenum. This case shows an unusual place of spontaneous perforation site of the stomach.

same area when he was five. An insizional biopsy was made and a squamous cell carcinoma based on Margolin's ulcer had detected. His whole blood cell count and biochemical parameters were normal. He had a normal chest radiograph. He had no specific story of a gastric or duodenal ulcer, gastritis, metabolic syndromes or Zollinger Ellison Syndrome. He had no pathological findings found while his preoperative physical examination.

Wide excision of tumor and reconstruction with a Chinese free flap has been made and routine postoperative care was given. 2 days later, unspecific symptoms were started such an unpreventable hiccups and a slight blunt pain. There was no pathological physical examination such as tympanic abdominal distention,

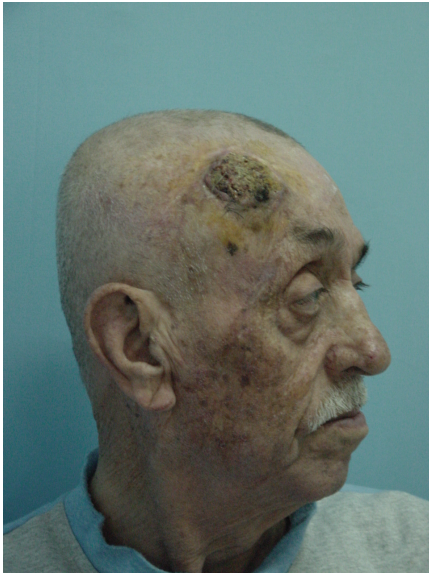Received:12.02.2010 • Accepted: 13.08.2011

Corresponding Author

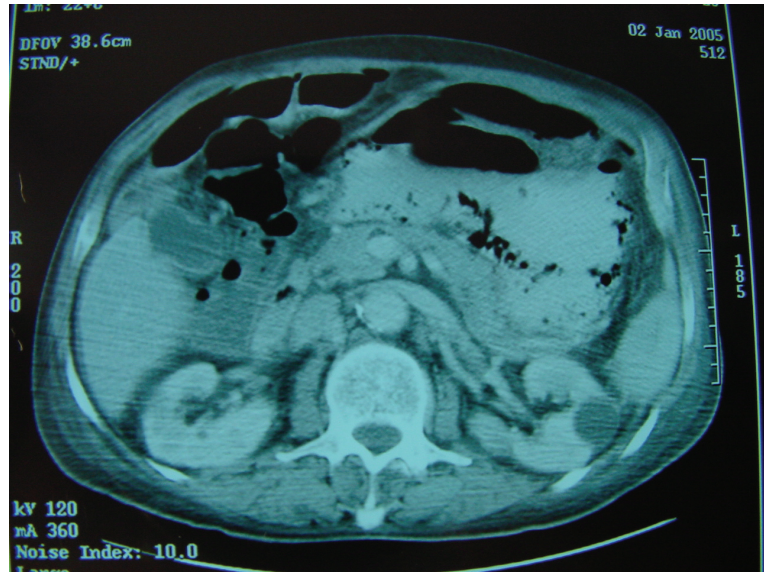Mert Demirel, MD  
Plastic, Reconstructive Surgery Clinic, Kahramanmaraş  
Government Hospital, Kahramanmaraş, Turkey  
Phone : +90 312 362 30 30/6175  
Fax : +90 312 319 81 39  
E-mail : drmertdemirel@yahoo.com

## Case Report

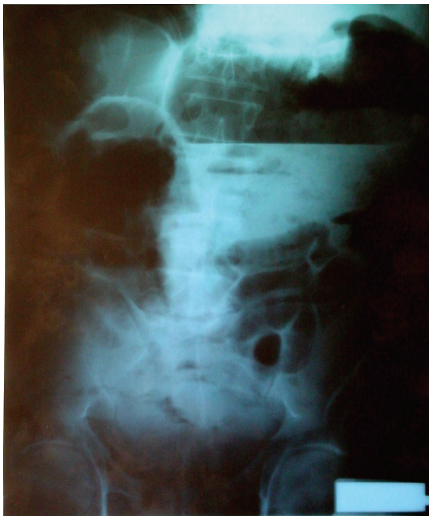A 75 year old male patient who has suffered a painless mass on his left frontal skin area for 5 years (Figure-1). He had a thermal burn on the



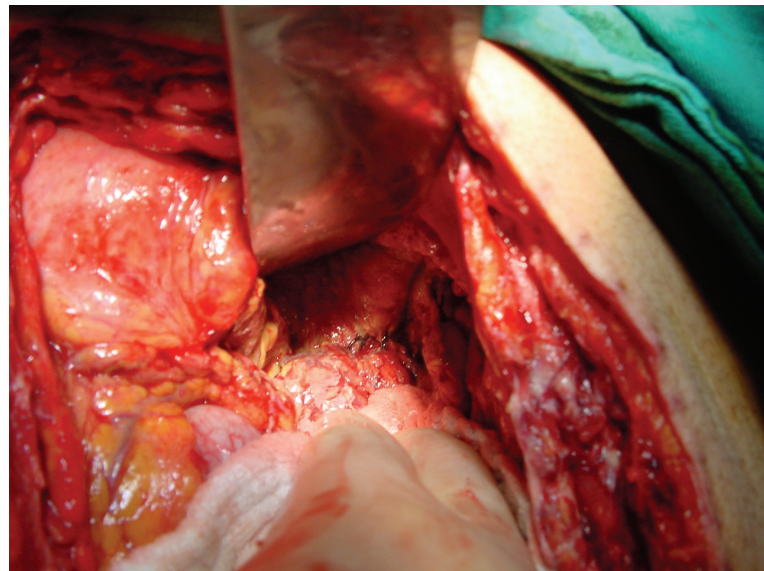
**Figure 1:** Lateral view of the squamous cell carcinoma on head.



**Figure 3:** Mesenteric region dirtiness at the posterior wall of the fundus.



**Figure 2:** A large amount free air under the diaphragm on plain abdominal radiography.



**Figure 4:** The perforation of the posterior wall of the gastric fundus was repaired.

rigidity or the abdominal parities, subcutaneous emphysema or evidence of shock that postulated as a tetralogy of gastric rupture by Millari(15).

Consultation with the General Surgery Clinic, a perforation has been suspected and a plain abdominal roentgenogram and computed tomography demonstrated a large amount free air under the diaphragm and the mesenteric region dirtiness (Figure-2, 3)

A laparotomy was performed, which revealed one perforation surrounded by necrotic tissue in the posterior wall of the gastric fundus. The necrotic tissue containing the perforation was trimmed and sutured in two layers and omentopexy was done (Figure-4). However, we were unable to detect any condition which would have caused gastric rupture. Pathological examination of the resected specimen from near the perforation showed

transmural necrosis with acute inflammation, but there were no findings such as ulcerations a muscle defect, or thrombosis, which could have to necrosis or perforation.

## Discussion

Spontaneous nontraumatic posterior perforation is rare, and high morbidity and mortality rates are reported for this condition in the literature<sup>12</sup>.

Posterior perforations tend to present late due to the insidious onset of symptoms. These perforations, if they have an ulcer component, penetrate into the retroperitoneal space or lesser sac. Gastric perforations were relatively more frequent in posterior perforations when compared with anterior perforations(13). Gastric perforation is an uncommon but very important case of medical practice. Using non-steroid anti-inflammatory agents, Zollinger Ellison Syndrome, traumas, malignancies, gastritis, or ulcers may cause gastric perforation but this condition is usually happened on the predictable areas, such as pylor or bulbous.

Gastric rupture following esophageal intubation and ventilation could occur, but is a very rare condition(14). A similar condition of the positive pressured gastric ventilation is, cardiopulmonary resuscitation (15). This unusual case shows that the acute abdominal syndrome of posterior wall fundus perforation limits itself because of its anatomic location, the inflammation does not spread out of the lesser omentum, proves the unspecific symptoms. Posterior perforations may be missed because of their rarity and anatomic location. The posterior perforated stomach can extravasate and track in the retroperitoneal space<sup>15</sup>. This may cause misdiagnosis such as; appendicular diseases, perinephric

abscess, retrocolic abscess(12,16-19). The resulting inflammatory collection or abscess can distract the surgeon from the true perforation site. An erect chest and abdominal roentograms should be done for patients with nonspecific abdominal symptoms. The diagnosis is often difficult even at celiotomy.

While practice of medicine is still surprising the doctors, these kinds of reports help us to be alert of uncommon conditions. We present herein a spontaneous posterior wall of gastric fundus perforation. We cannot find a case report with these specialties in the literature. Therefore we really like to add this interesting case to the literature.

## KAYNAKLAR

1. Svanes C: Trends in perforated peptic ulcer: incidence, etiology, treatment and prognosis. *World J Surg.* 2000 Mar; 24(3): 277-83
2. Albo R, De Lorimier AA, Silen W: Spontaneous rupture of the stomach in the adult. *Surgery* 1963; 53: 797-805
3. Akram J, Yawad, A, Al-Rabie, Anjum Hadi, A, Al-Sowialeem, A, Al-Rawaf, Bashar Abu-Touk, T, Al-Karfi, A, Al-Sammarai Spontaneous neonatal gastric perforation. *Pediatr Surg Int.* 2002; 18: 396-399
4. Leone R.J,Jr, Krasna I.H: "Spontaneous" Neonatal Gastric Perforation: Is It Really Spontaneous? *Journal of Pediatric Surgery* 2000 July; 35(7): 1066-1069
5. Adachi Y, Takamasu H, Hiroyuki N, Hiroyuki T, Motoi M, Hiroshi: A Spontaneous Rupture of the Stomach in Preschool Age Children: A Report of Two Cases. *Jpn Surg Today* 1998; 28: 79-82
6. Waxman I, Gardner JD, Jensen RT, Maton PN: Peptic ulcer perforation as the presentation of Zollinger-Ellison syndrome. *Dig Dis Sci.* 1991Jan; 36(1): 19-24
7. Fernandez Lobato R, Alvarez Sanchez J, Angulo F, Aramburo JA, Fradejas JM, Carabias A, Ramos JL, Moreno Azcoita M: Perforation as the first symptom of a gastric carcinoma. *Rev Esp Enferm Dig.* 1994 Jun; 85(6): 489-90.
8. Solis-Caxaj CA, Wacrenier A, Caudrelier JM, Proye C: Gastric metastasis of ductal breast cancer revealed by a perforated ulcer. *Gastroenterol Clin Biol.* 2004 Jan; 28(1): 91-2.
9. Suzaki N, Hiraki A, Ueoka H, Aoe M, Takigawa N, Kishino T, Kiura K, Kanehiro A, Tanimoto M, Harada M: Gastric perforation due to metastasis from adenocarcinoma of the lung. *Anticancer Res.* 2002 Mar-Apr; 22(2b): 1209-12
10. Fra J, Arranz F, Rubiales AS, Paz Perez M, Buesa JM: Gastric perforation caused by metastasis of breast cancer in a man. *Presse Med* 1996 Sep14; 25(26): 1215
11. Angio LG, Versaci A, Rivoli G, Fracassi MG, Rosato A, Pacile V, Famulari C: Hemorrhage and Gastric perforation in patients with percutaneous gastrostomy. *Ann Ital Chir* 2003 Mar-Apr; 74(2): 195-201
12. Haylar J, Macpherson A, Bjarnason I: Gastro protection and nonsteroidal anti-inflammatory drugs (NSAIDs). Rationale and clinical implications. *Drug Saf* 1992 Mar- Apr; 7(2): 86-105
13. Weston-Dacies WH, Perkiewicz M, Szczygiel B: Retroperitoneal extravasation from perforated duodenal ulcer. *Br J Surg* 1988; 75: 878-9
14. Chin-Ho Wong, Pierce KH Chow, Hock-Soo Ong, Weng-Hoong Chan, Lay-Wai Khin, Khee-Chee Soo: Posterior perforation of peptic ulcers: Presentation and outcome of an uncommon surgical emergency. *Surgery* 2004; 135: 321-5
15. Lelcuk S, Kaplan O, Leibovitz I, Rozin RR: Stomach rupture caused by false intubation of the esophagus. *Isr Med J Sci* 1990;26:167-168.
16. Spoomans I, Van Hoorenbeeck K, Balliu L, Jorens PG. Gastric perforation after cardiopulmonary resuscitation: review of the literature. *Resuscitation.* 2010 Mar;81(3):272-80. Epub 2010 Jan 12
17. Hashmonai M, Abrahamson J, Erlik D, Schramek A:Retroperitoneal perforation of duodenal ulcers with abscess formation: a report of 4 cases and survey of the literature. *Ann Surg* 1971; 173: 409-14
18. Britt LG, Wolf Ry: Postbulbar ulcer with retrocecal abscess:a case report. *Arch Surg* 1966; 92: 98-100
19. Mistry BM, Holloway RF, Caravella PA, Riskin DJ, Mazuksi JE, Johnson FE: Perforated posterior duodenal ulcer: a case report and literature review. *Contemporary Surg* 2001; 57(9): 453-5
20. Yoshida H, Onda M, Tajiri T, Tanai N, Matsukura N, Tokunaga A, et al: A case of abscess caused by a penetrating duodenal ulcer. *Hepatogastroenterology* 1999 Jul-Aug; 46(28): 2379-81