

## A HEMANGIOPERICYTIC MENINGIOMA

### Case Report

Ayşe Sertçelik\*    Nimet Kuyucu\*\*    Yücel Kanpolat\*\*\*    Orhan Bulay\*\*\*\*

The concept of hemangiopericytoma, which is a tumor of pericytes of blood vessels, was proposed by Stout and Murray in 1942 (13). However, Bailey, Cushing and Eisenhardt had introduced in 1928 the name of «angioblastic meningioma» for the meningiomas, which were rich of vascular channels with or without an overgrowth of closely packed elongated or oval cells (1). These type of meningiomas are generally fairly rare, they demonstrate an aggressive behavior and can metastasize. Therefore, these meningiomas have importance from clinical point of view.

In view of the rarity of this type of meningioma and the controversy on its cell's origin, we found it useful to describe one case of hemangiopericytic meningioma, diagnosed in our department.

### CASE REPORT

The case was 42 years old man, who was operated in October 1984, with a diagnosis of a right parieto-occipital meningioma. Its histopathological diagnosis was «angioblastic meningioma» (The histological features are concordant with hemangiopericytic meningioma). Two years later, the patient had the same complaint of increased intracranial pressure. On brain scan a large circumscribed area of increased

---

\* Associated Prof. in the Department of Pathology, University of Ankara.

\*\* Assistant in the Department of Pathology, University of Ankara.

\*\*\* Associated Prof. in the Department of Neurosurgery, University of Ankara.

\*\*\*\* Professor in the Department of Pathology, University of Ankara.



radioisotope uptake was seen on the right parieto-occipital region. The second operation performed on 8 December 1986, revealed a regrowth of a reddish brown mass in the same location as previously. At operation severe brain edema complicated with hematoma of the tumor was seen. The tumor invade the dura mater and extend to the tentorium, but there was no infiltration into the brain substance. A radical resection of the tumor was performed. There was no sign of metastatic disease.

The microscopic examination of the tumor revealed very cellular configuration : the spindle and oval shaped cells surrounded the endothelial-lined channels and they were arranged in solid masses or sheets (Fig. 1). The endothelial cells of these vascular channels were flat and inconspicuous. Mitotic figures were frequent. Necrosis was seen in some area. The reticulin stain showed a typical pattern of fine reticulin fibers around a single or small group of tumor cells about the vascular spaces (Fig. 2).

In the view of these findings, the histopathological diagnosis was «Hemangiopericytic Meningioma».

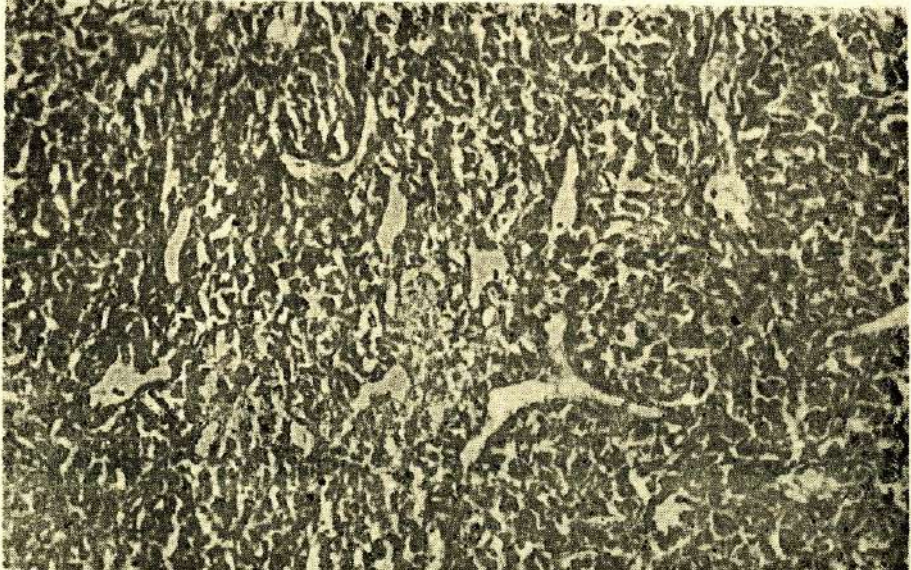


Fig. 1 : Hemangiopericytic meningioma : Numerous endothelial-lined vascular channels interposed among sheets of oval, elongated cells (H.E. x 20).



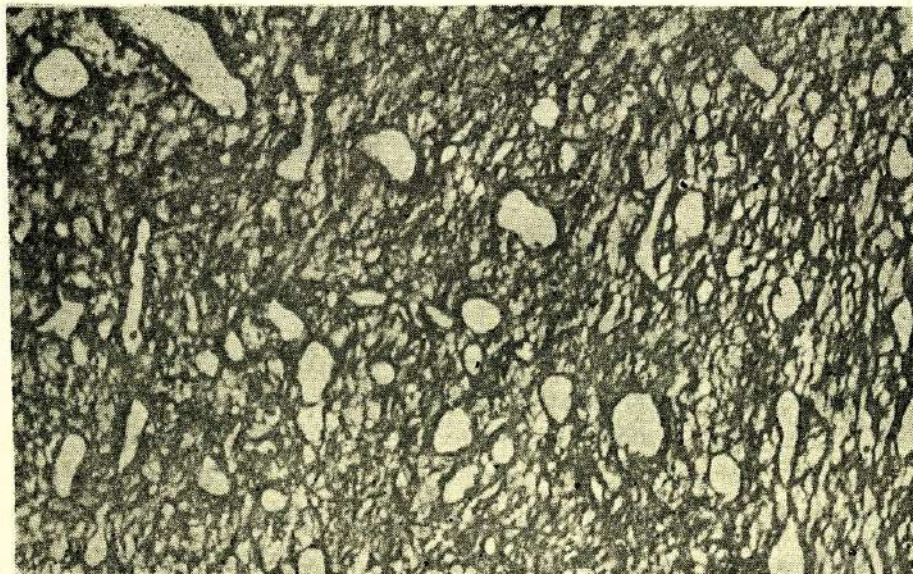


Fig. 2 : Collar of silver staining fibers is seen around vessels and fine network of fibers interlacing with tumor cells (Reticulin stain x 20).

### DISCUSSION

The rare and distinct intracranial neoplasm of «angioblastic meningioma» was originally depicted by Bailey and associated in 1928, and they pointed out of the aggressive course of these tumors (1).

Kernohan and Uihlein included hemangiopericytomas in sarcomas of the brain and commented only 26 cases of hemangiopericytoma in their book «Sarcomas of the Brain». They emphasized the distinct histological features and aggressive clinical course of the lesion (4).

Skullerud and Loken found only five cases of hemangiopericytoma in 161 cases of meningioma (2 %) and three of them had recurrences (12).

Between the 1238 meningiomas examined by Jellinger and Slowik only 17 (1.4 %) were hemangiopericytoma and 6 (35 %) of them recurred after complete removal (3).



Goellner and associates studied 26 hemangiopericytomas of the meninges. All of them showed an aggressive course, the recurrence rate was 80 % and metastases rate was 23 % (2). The recurrence appeared a mean of five year after initial therapy. In our single case the recurrence has developed in two years.

The occurrence of the hemangiopericytoma in the brain has been controversial and disputed by many authors : some investigators such as Russell and Rubinstein, Pitkethly and Palacios, in keeping with the original definition provided by Bailey et al, consider these tumors to be a type of angioblastic meningioma (8,9,11), but others mentioned a lack of intermediate features between hemangiopericytoma and meningioma and agreed that the two tumors were separate entities (2,6,10). Popoff suggest that the studies of fine structure of intracranial hemangiopericytoma conforms in all respects to hemangiopericytoma encountered in other organ system and propose their exslusion from the large group of meningiomas (10). McMaster stated that the pericyt is found in the capillaries and venules of practically all types of tissue, so it is not surprising that hemangiopericytomas have been reported as arising in many areas of the body, including nervous system, bone and viscera (7).

In our case the histopathologic appearance and the distribution of the reticulin fibers were identical to the hemangiopericytoma encountered in other organ or tissues, so the definition of «Hemangiopericytoma» must be sufficient for the designation of these intracranial neoplasms.

## ÖZET

Bu makalede, nüks gösteren bir hemangioperistik menengioma olgusu sunulmuştur. Bu ender olgunun histopatolojik özellikleri diğer yumuşak doku hemangioperisitomalarınınkini taşımaktadır. Bu nedenle, bu tip menenjiomalara «hemangioperisitoma» tanımının yeterli olduğu kanısındayız.

## SUMMARY

### A Hemangiopericytic Meningioma

A case of a recurrent hemangiopericytic meningioma is reported. The histopathological features of this rare case was similar to that of hemangiopericytomas of soft tissues. Therefore the designation of «Hemangiopericytoma» must be sufficient for these meningiomas.

## REFERENCES

1. Bailey, P., Cushing, H., Eisenhardt, L. : Angioblastic Meningiomas. *Arch Pathol.* 6 : 533, 1928.
2. Goellner, J.R., Laws, E.R., Soule, E.H. et al. : Hemangiopericytoma of the meninges. *Mayo Clinic Experience. Am J Clin Pathol.* 70 : 375, 1978.
3. Jellinger, K., Slowik, F. : Histological subtypes and prognostic problems in meningiomas. *J Neurol.* 208 : 279, 1975.
4. Kernohan, J.W., Uihlein, A. : Sarcomas of the brain. Springfield III. Charles C Thomas. 1962 pp 108-119.
5. Kruse, F.Jr. : Hemangiopericytoma of the meninges (Angioblastic meningioma of Cushing and Eisenhardt) *Neurology.* 11 : 771, 1961.
6. Lesoin, F. : Hemangiopericytic meningioma of the pineal region. *Eur Neurol.* 23 (4) : 274, 1984.
7. McMaster, M., Soule, E.H., Ivins, C.J. : Hemangiopericytoma. *Cancer.* 36 : 2232, 1975.
8. Palacios, E., Behrooz, A.K. : Malignant metastasizing angioblastic meningiomas. *J Neurosurg.* 42 : 185, 1975.
9. Pitkethly, D.T., Hardman, J.M., Kempe, L.G. et al. : Angioblastic meningiomas. *J Neurosurg.* 32 : 539, 1970.
10. Popoff, N.A., Malinin, T.I., Rosomoff H.L. : Fine structure of intracranial hemangiopericytoma and angiomatous meningioma. *Cancer.* 34 : 1187, 1974.



11. Russell, D.S., Rubinstein L.J. : Pathology of tumors of the nervous system  
Baltimore, Williams and Wilkins. 1971 pp 58-60, 90.
12. Skullerud, K., Loken. A.C. : The prognosis of meningiomas. Acta Neuropathol  
(Berl.) 29 : 337, 1974.
13. Stout, A.P., Murray M.R. : Hemangiopericytoma : A vascular tumor featuring  
Zimmermann's pericytes. Ann. Surg. 116 : 26, 1942.